

# Indian Thyroid Society

## Quiz – 16/11/2022

Dr. PR. Gokulakrishnan, MD, FRCR, M.Med

Professor of Radiology

Sri Ramachandra Institute for Higher Education and Research  
Chennai

## Question 1

What needle size is preferable for doing thyroid FNAC ?

- A] 18 g
- B] 20 g
- C] 22 g
- D] 24 g

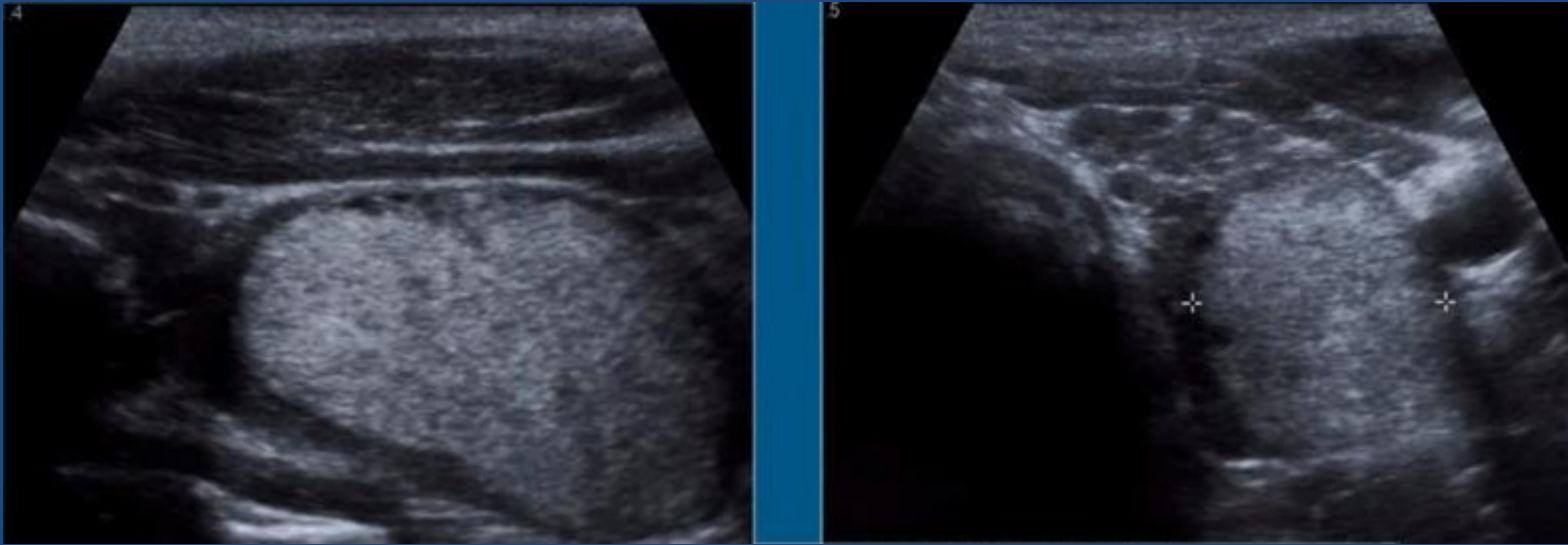
## Question 2

What is true regarding consistency of a nodule

- A] Hard nodules are more likely to be benign
- B] Soft nodules are more likely to be malignant
- C] Hard nodules are more likely to be malignant
- D] Cystic nodules are more likely to be malignant

# Question 3

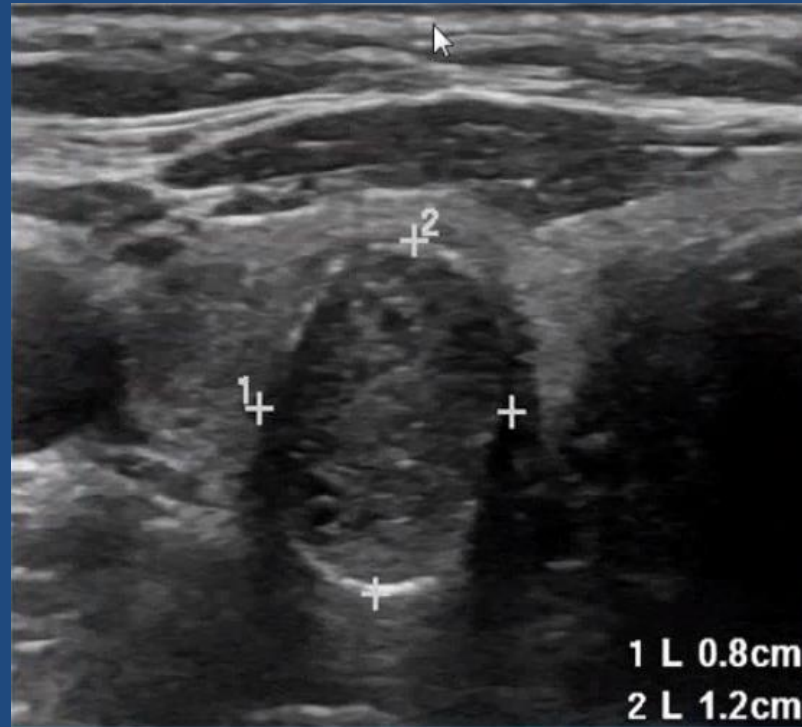
How do you comment on echogenicity of this nodule ?



- A. Marked hypoechoic nodule
- B. Hypoechoic nodule
- C. Isoechoic nodule
- D. Hyperechoic nodule

## Question 4

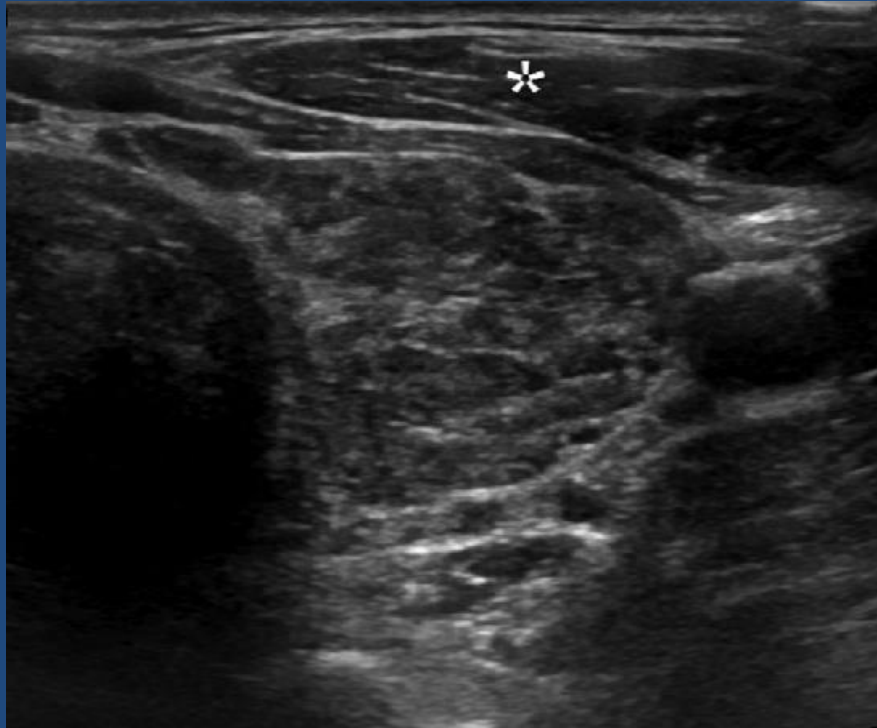
What is the shape of this nodule ?



- A. Not taller than wider
- B. Taller than wider
- C. Wider than taller
- D. Neither taller or wider

## Question 5

How do you interpret this USG thyroid as ?



- A. Multinodular goitre
- B. True nodule
- C. Pseudonodules
- D. Thyroid lymphoma

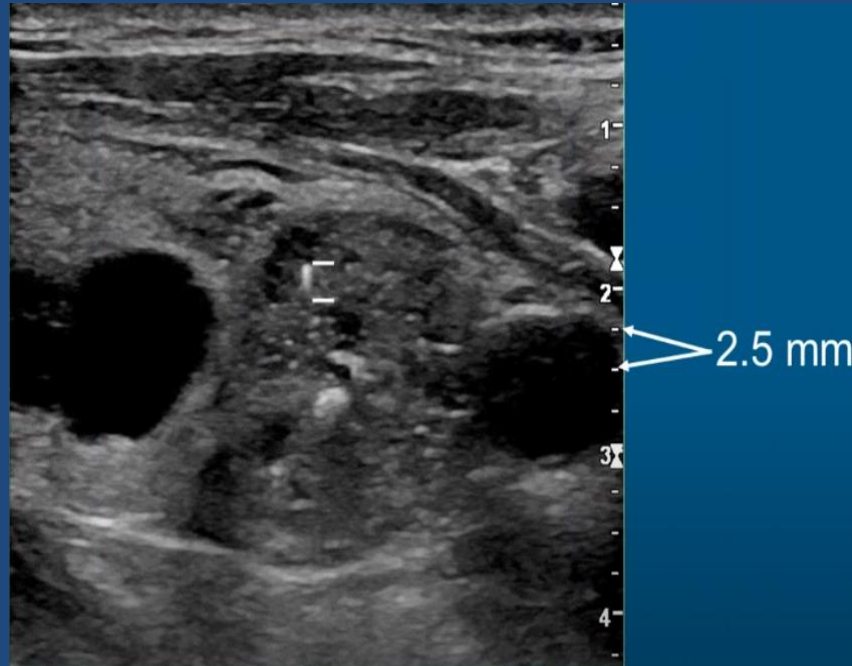
## Question 6

Which of these nodules do not warrant thyroid FNAC ?

- A] ACR-TR1 and TR2
- B] ACR-TR2 and TR3
- C] ACR-TR3 and TR4
- D] ACR-TR4 and TR5

# Question 7

How do you name this artefact ?

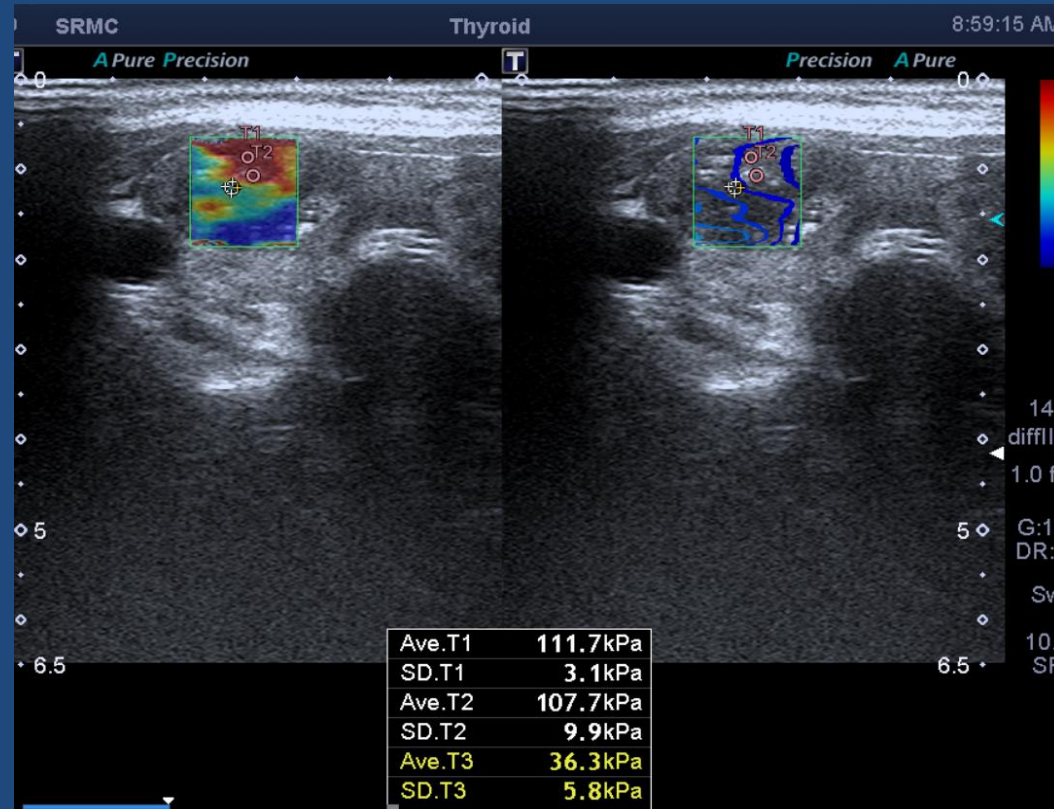


- A. Comet tail artefact
- B. Ring down artefact
- C. Posterior acoustic shadow
- D. Posterior acoustic enhancement



## Question 8

What is the name of this imaging technique ?



- A] Sheer wave elastography
- B] Strain elastography
- C] Micropure imaging
- D] Microvascular Doppler

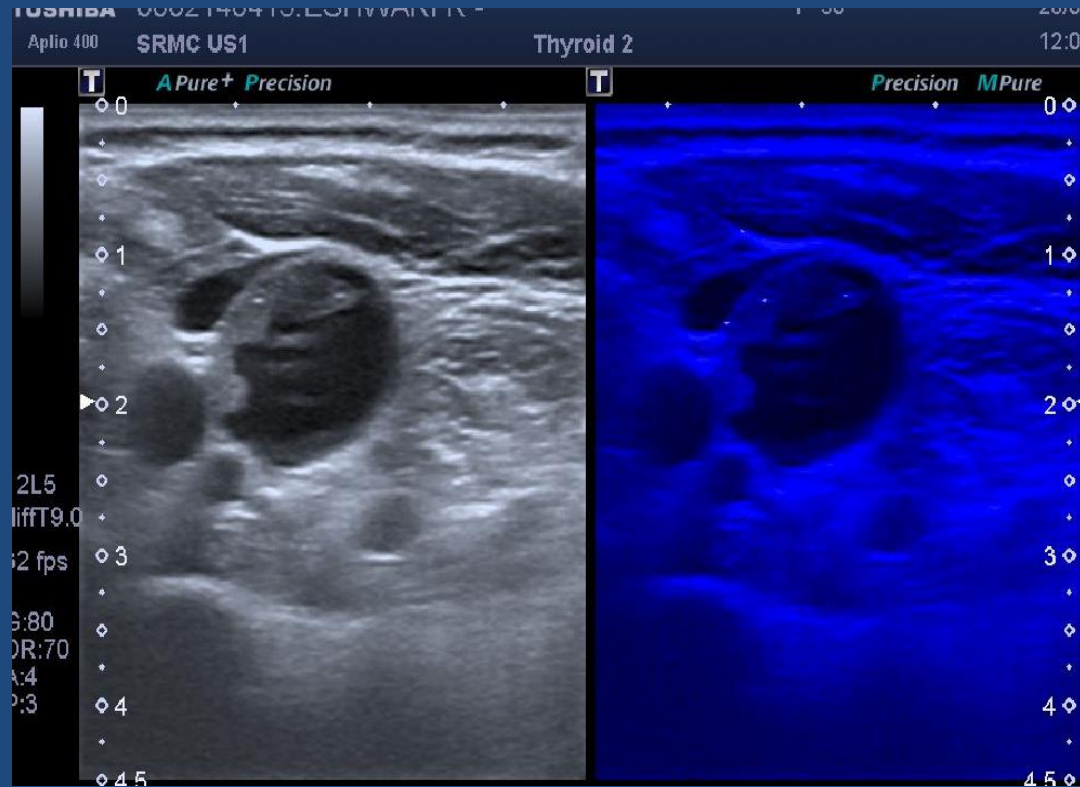
## Question 9

What are the key points in assessing the malignancy of a thyroid nodule ?

- A] Composition , echogenicity, margins, calcifications, shape
- B] Composition, vascularity, margins, calcifications
- C] Vascularity, echogenicity, margins, calcification, shape
- D] Composition, vascularity, echogenicity, shape, margins

## Question 10

What is the name of this imaging technique ?



- A. Sheer wave elastography
- B. Strain elastography
- C. Micropure imaging
- D. Microvascular Doppler

# Answers and Discussion

## Question 1

What needle size is preferable for doing thyroid FNAC ?

- A] 18 g
- B] 20 g
- C] 22 g
- D] 24 g

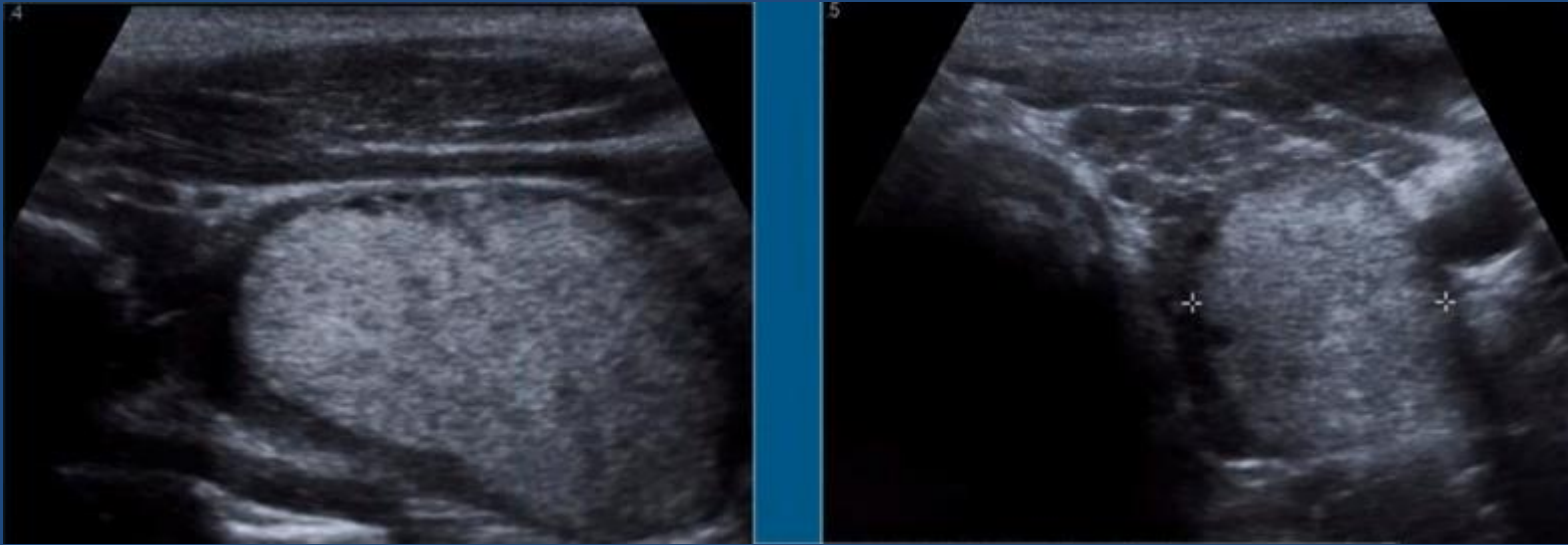
## Question 2

What is true regarding consistency of a nodule

- A] Hard nodules are more likely to be benign
- B] Soft nodules are more likely to be malignant
- **C] Hard nodules are more likely to be malignant**
- D] Cystic nodules are more likely to be malignant

# Question 3

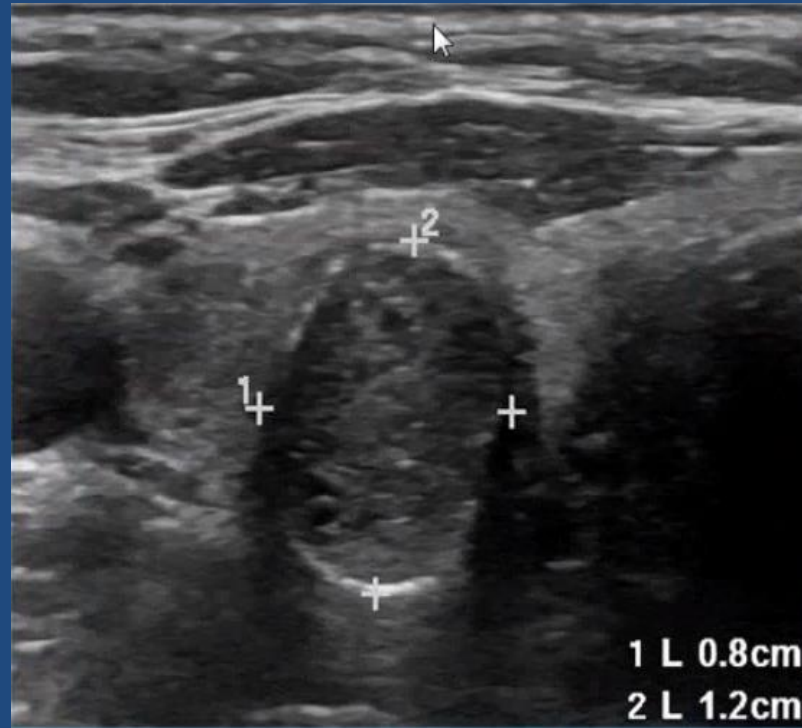
How do you comment on echogenicity of this nodule ?



- A. Marked hypoechoic nodule
- B. Hypoechoic nodule
- C. Isoechoic nodule
- D. Hyperechoic nodule**

## Question 4

What is the shape of this nodule ?

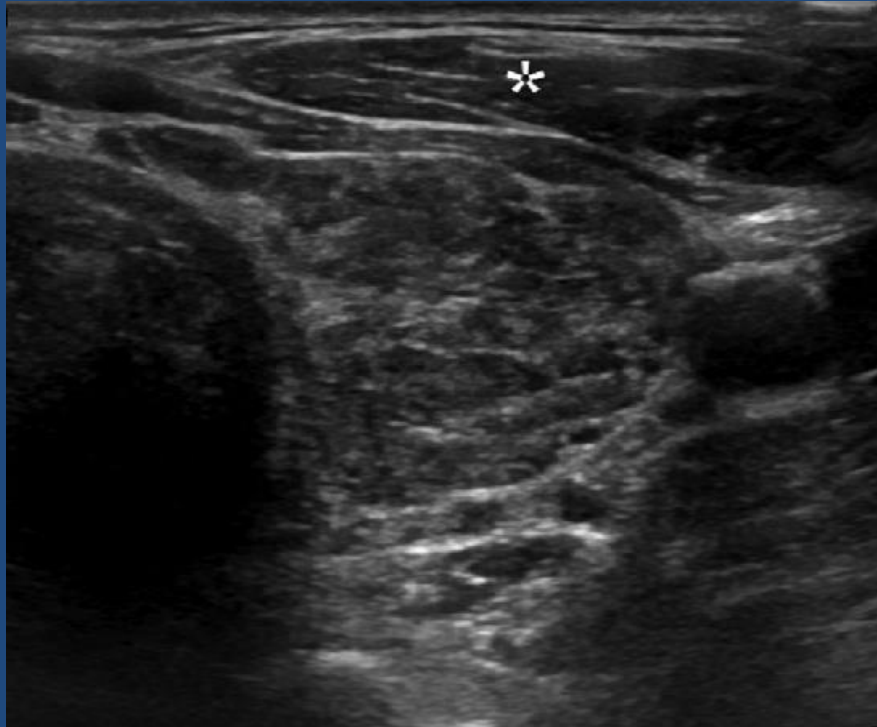


- A. Not taller than wider
- B. Taller than wider**
- C. Wider than taller
- D. Neither taller or wider



## Question 5

How do you interpret this USG thyroid as ?



- A. Multinodular goitre
- B. True nodule
- C. Pseudonodules
- D. Thyroid lymphoma

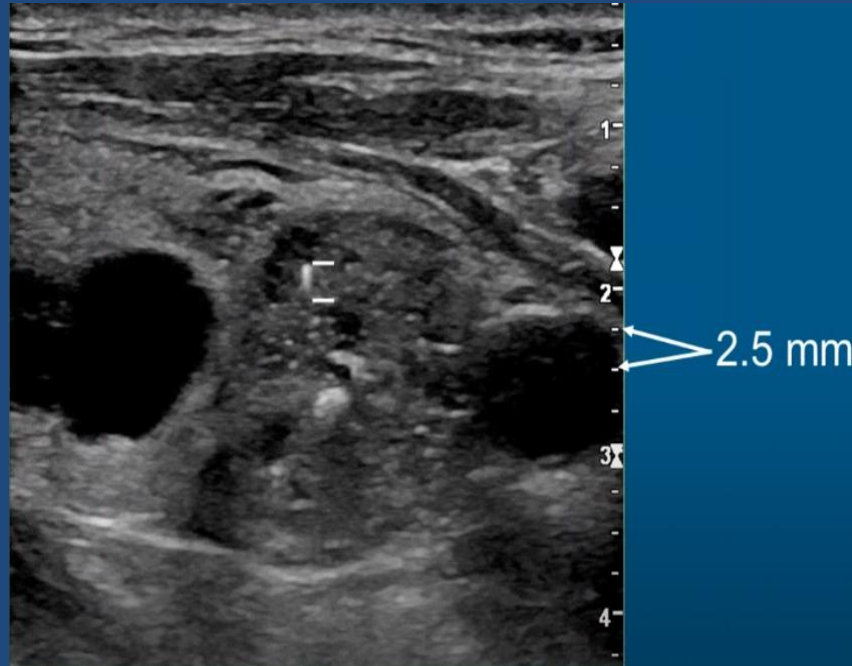
## Question 6

Which of these nodules do not warrant thyroid FNAC ?

- A] ACR-TR1 and TR2
- B] ACR-TR2 and TR3
- C] ACR-TR3 and TR4
- D] ACR-TR4 and TR5

# Question 7

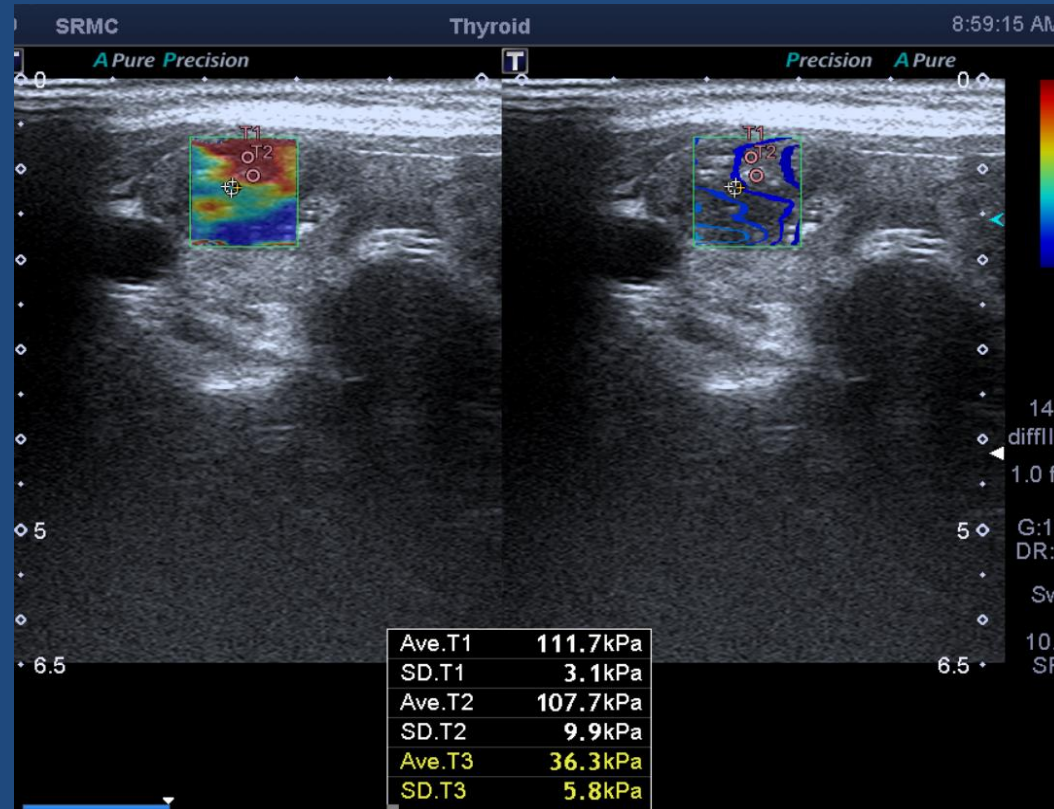
How do you name this artefact ?



- A. Comet tail artefact
- B. Ring down artefact
- C. Posterior acoustic shadow
- D. Posterior acoustic enhancement

## Question 8

What is the name of this imaging technique ?



A] Sheer wave elastography

B] Strain elastography

C] Micropure imaging

D] Microvascular Doppler

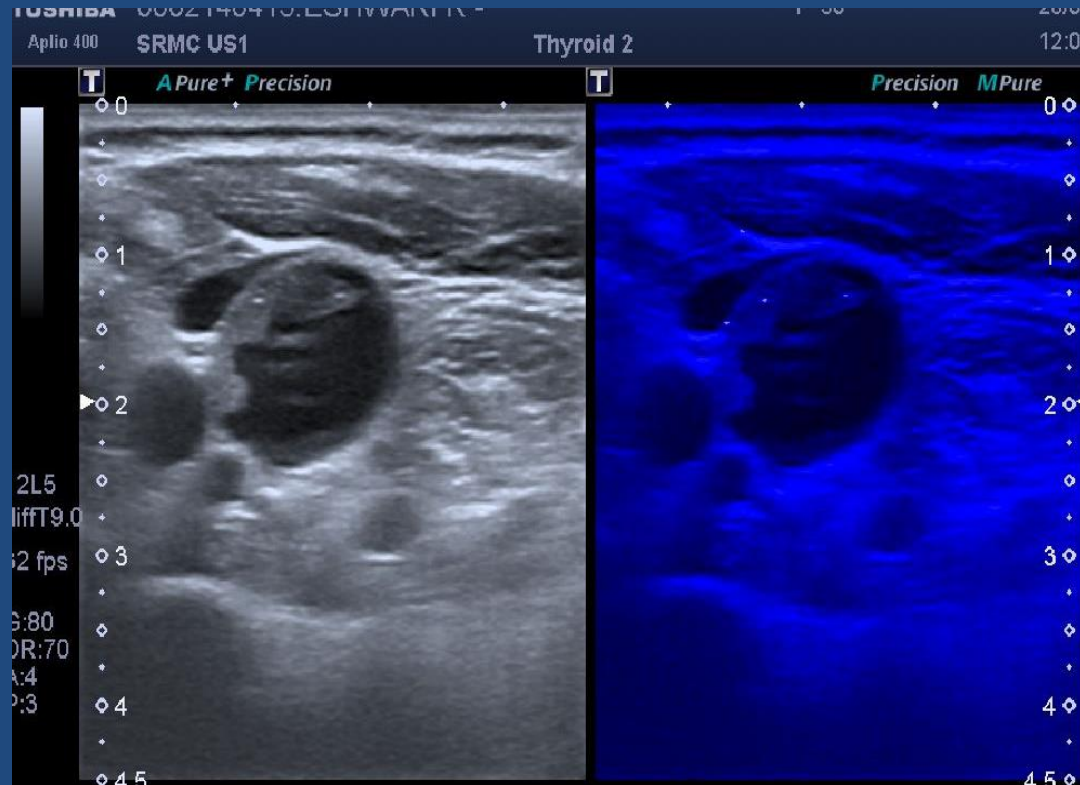
## Question 9

What are the key points in assessing the malignancy of a thyroid nodule ?

- A] Composition , echogenicity, margins, calcifications, shape
- B] Composition, vascularity, margins, calcifications
- C] Vascularity, echogenicity, margins, calcification, shape
- D] Composition, vascularity, echogenicity, shape, margins

## Question 10

What is the name of this imaging technique ?



- A. Sheer wave elastography
- B. Strain elastography
- C. Micropure imaging
- D. Microvascular Doppler

Thank You